

Regionally Specific Cortical Thinning in Children with Sickle Cell Disease

Gregory R. Kirk¹, M. Ryan Haynes^{1,2}, Susan Palasis¹, Clark Brown³, Thomas G. Burns⁴, Megan McCormick⁴ and Richard A. Jones^{1,5}

¹Department of Radiology, Children's Healthcare of Atlanta, Atlanta, GA 30342, USA, ²Department of Biomedical Engineering, Georgia Institute of Technology, Atlanta, GA 30332, USA, ³Department of Hematology, ⁴Department of Neuropsychology, Children's Healthcare of Atlanta, Atlanta, GA 30342, USA and ⁵Department of Radiology, Emory University, Atlanta, GA 30332, USA

Sickle cell disease (SCD) is a chronic disease with a significant rate of neurological complications in the first decade of life. In this retrospective study, cortical thickness was examined in children with SCD who had no detectable abnormalities on conventional magnetic resonance imaging/magnetic resonance angiography. Regional differences in cortical thickness from SCD were explored using age-matched healthy controls as comparison. A comparison analysis was done for SCD ($n = 28$) and controls ($n = 29$) based on age (5–11; 12–21 years), due to the age-dependent variation in cortex maturation. Distinct regions of thinning were found in SCD patients in both age groups. The number, spatial extent, and significance ($P < 0.001$) of these areas of thinning were increased in the older SCD group. Regions of interest (ROIs) were defined on the areas of highly significant thinning in the older group and then mapped onto the younger cohort; a multiparametric linear regression analysis of the ROI data demonstrated significant ($P < 0.001$) cortical thinning in SCD subjects, with the largest regions of thinning in the precuneus and the posterior cingulate. The regionally specific differences suggest that cortical thickness may serve as a marker for silent insults in SCD and hence may be a useful tool for identifying SCD patients at risk for neurological sequelae.

Keywords: cortical thickness, magnetic resonance imaging, sickle cell disease

Introduction

Sickle cell disease (SCD) is one of the most prevalent genetic disorders, affecting over 70 000 people in the United States. The term sickle cell disease encompasses the homozygous form of the disease (sickle cell anemia) and conditions where a person with the heterozygous form (sickle cell trait) also has another abnormal hemoglobin allele. The pathophysiology of SCD is not completely understood. Increased red cell adhesion, coupled with increased shear stress due to anemia may initiate injury to the endothelial cells of the cerebral arteries. This in turn initiates other processes including oxidative injury of the vessel wall, inflammation, abnormal vasomotor regulation, and increased coagulation (Hillery and Panepinto 2004). The anemia associated with SCD results in hyperemia and vasodilation throughout the body and the resulting chronic increase in cerebral blood flow leads to an inability to further increase perfusion of the brain during periods of hypoxic stress.

Over recent decades, the development of treatment regimens—including prophylactic penicillin, pneumococcal vaccination, and routine screening with transcranial Doppler ultrasound—has dramatically increased the life expectancy of patients with SCD (Platt et al. 1994) and has led to increasing

attention on the chronic adverse effects of SCD that significantly impair quality of life. Patients have a high incidence of overt stroke that peaks in childhood (Ohene-Frempong et al. 1998) and a high recurrence rate in those who are not chronically transfused. Additionally, covert infarction, in the absence of neurological symptoms and signs, affects up to a quarter of children with SCD screened with magnetic resonance imaging (MRI) (Pegelow et al. 2002). These lesions are often unilateral, small, and focal, and patients with such infarcts are at greater risk for cognitive decline (Watkins et al. 1998). Structural imaging abnormalities, including overt stroke and silent infarct, have been associated with the severity and the type of cognitive impairment in several studies (Grueneich et al. 2004; Kral et al. 2006). However, the associated cognitive deficits are widespread and have also been found in children without any obvious lesions (Steen et al. 2005).

The inability of conventional MRI/magnetic resonance angiography (MRA) to predict which patients are at risk for cognitive decline has led several groups to investigate other neuroimaging markers of cytoarchitectonic changes in the brains of sickle cell patients. One study reported a significant reduction in T_1 in a pediatric sickle cell population with respect to an age-matched normal control group (Steen et al. 1999). A voxel-based morphometry analysis of group differences between a sickle cell patient population and a control group found a significant reduction in white matter density in the sickle cell population (Baldeweg et al. 2006). In another study, a semiautomated procedure was used to classify tissue types and compute quantitative volumetric data on a group of normal controls and sickle cell patients. This study found a reduced gray matter volume in the sickle cell population, with a more significant reduction in subcortical structures than in the cortical volume (Steen et al. 2006).

However, the question of whether sickle cell patients have cortical thickness abnormalities that are undetectable with conventional MRI has not been addressed. Measurements of cortical thickness have been used to study a variety of neurological disorders including schizophrenia, Alzheimer's disease, and autism. This approach has been able to detect spatially localized differences in these populations, compared with healthy controls, which were not apparent on radiological evaluations of the individual patients (Hadjikhani et al. 2006; Du et al. 2007; Goghari et al. 2007). We hypothesized that because cognitive deficits are found in children with SCD, even when they have no overt neurological defects and have both a normal MRI scan and a normal MRA, significant differences in cortical thickness may exist between patients with SCD and a control population.

Materials and Methods

Subjects

For the patients with SCD, the MRI examinations were part of the normal standard of care for this population and the use of the data was approved, as a retrospective study, by the Institutional Review Board (IRB). The sickle cell population was restricted to patients with the homozygous form of the disease (sickle cell anemia), and the standard of care magnetic resonance examination for these patients included an MRA. The images were reviewed by an experienced pediatric neuro-radiologist to verify the absence of radiologically evident pathology from the structural images and the MRA. All subjects who had a negative MRI examination during the study period covered by the retrospective IRB were enrolled in the study. The normal control population consisted of healthy volunteers who were recruited for a functional MRI (fMRI) study which included the acquisition of volumetric MRI data. These volunteers gave written informed consent to participate in an IRB-approved study and had their MRI evaluated by an experienced pediatric neuroradiologist to verify the absence of radiologically evident pathology from the structural images. Targeted recruiting of the control population on the basis of age and gender was used to obtain as unbiased a sample as possible with respect to the sickle cell population. A total of 30 volunteers and 33 sickle cell patients with normal MRI examinations were enrolled in the study. All but one of the patients with SCD (96%) declared themselves to be African-Americans, the other was a "nonwhite Hispanic." The control population consisted of 8 (27%) African-Americans, 1 Hispanic, and 21 (70%) Caucasian subjects. The 3 youngest sickle cell patients (3.1, 4.1, and 4.4 years, respectively) were much younger than the youngest control (6.3 years) and were hence excluded from the analysis.

One factor that complicates the analysis of the evolution of the cortical thickness with age is that different regions of the brain mature at different rates. Recent reports showed that the peak cortical volume for most of the brain can be described by a cubic model with a peak in cortical volume between 7 and 12 years of age, with the exact location of the peak being both region and gender specific (Lenroot et al. 2007; Shaw et al. 2008). Once the peak is passed, the changes in the cortical volume appear to be well characterized by a linear function. Thus, the application of an analysis that uses a linear model to the whole group of subjects, or those aged below 12 years of age, is of questionable value. For this reason, we split the subjects into 2 groups (for each population): the first (younger) group consisted of subjects of less than 12 years of age and the second (older) group consisted of all subjects aged 12 years and above. To test for outliers in these 2 groups, a Grubbs' test was performed. No outliers were detected in either the younger or the older control groups or the younger SCD group, but one outlier was found in the older SCD group and this subject was excluded from the analysis. One subject had to be discarded from each group for technical reasons (see Results section), thus 29 healthy controls and 28 subjects with SCD were included in the study. The younger normal control population consisted of 14 subjects with a mean age of 9.0 years (standard deviation [SD] = 1.9 years, range = 6.3–11.9 years), and the younger sickle cell population consisted of 16 subjects with a mean age of 8.0 years (SD = 2.1 years, range 5.2–11.9 years). The older normal control population consisted of 15 subjects with a mean age of 15.6 years (SD = 2.4 years, range = 12.2–20.4 years), and the older sickle cell population consisted of 12 subjects with a mean age of 14.6 years (SD = 1.0 years, range 12.4–18.6 years). The detailed demographics of the 2 groups are presented in Tables 1 and 2 in the Supplementary Information online. There were no statistically significant differences in the age distribution of the populations. No neuropsychological testing was performed on the sickle cell population in this retrospective study; hence, it is not known if there were significant differences in cognitive abilities between the 2 groups.

MRI Acquisition

The MRI data were acquired on 1.5-T Siemens scanners using a 3-dimensional spoiled gradient echo (SPGR) sequence with time repetition = 7.9 ms, time error = 3.0 ms, a sampling bandwidth of 190

Hz/pixel, and a flip angle of 20°. The images were acquired in the sagittal plane with a field of view of 256 mm², an acquisition matrix of 256², and a slice thickness of 1 mm, resulting in 1-mm isotropic spatial resolution. Sufficient slices were acquired to cover the full extent of the brain and scalp in the left–right direction. The images were acquired using either a 4- or a 12-channel receive-only head coil, and the signal intensities were corrected on the basis of a reference scan using the standard software on the scanner. For the patients with SCD, the standard of care of examination included diffusion imaging, a time of flight MRA, T₂-weighted and FLAIR imaging, in addition to the T₁-weighted volume described above.

Segmentation and Surface Extraction

The cortical surface extraction was performed using Freesurfer v3.0 (<http://surfer.nmr.mgh.harvard.edu/>). This software has been described in detail in the literature (Fischl et al. 1998; Dale et al. 1999; Fischl, Sereno, Dale 1999, Fischl and Dale 2000; Fischl et al. 2002), so only a brief description of the process is given here. Freesurfer attempts to reconstruct 2 surfaces—the pial surface and white matter surface—which serve as the basis for cortical thickness estimates. These surfaces are estimated through a series of computationally intensive steps in which the original MRI volumetric SPGR acquisitions undergo intensity normalization and skull stripping followed by automated segmentation of subcortical structures and white matter (Fischl et al. 2002). The white matter surface is estimated first by using the prior segmentations as a starting point and the sulcal and gyral folds as guides to create a subvoxel, topologically correct surface (Dale et al. 1999; Fischl, Sereno, Dale 1999). The pial surface is estimated by deforming the white matter surface outward to find the gray matter/cerebrospinal fluid boundary. The cortical thickness is computed as the average of the distance between the surfaces in order to avoid confounds from certain pathological conditions (Fischl and Dale 2000). Validations of this method for estimating cortical thickness have been described in several papers (Rosas et al. 2002; Kuperberg et al. 2003).

Group Analysis

The reconstructed surfaces are coregistered across subjects by using anatomical markers (e.g., the Sylvian fissure) (Fischl et al. 1998; Fischl, Sereno, Tootell, Dale 1999). Thus, for each vertex on the average surface, we have a mapping to the corresponding vertex on the surface of each subject. For each category (sickle cell patient, normal control) and each group (younger, older), a linear model of the cortical thickness as a function of age is calculated at each vertex (triangle) on the surface. To test for significant differences in the cortical thickness, a linear fit was calculated such that the slope of the line for the 2 groups is the same, but the vertical offset (representing thickness) was allowed to freely vary such that the best fit to the data for each category is obtained. Inference was then performed at each vertex on the statistical significance of the difference in vertical intercept between the 2 groups while regressing out the effect of age. For each of the analyses, the resulting parametric maps were overlain on the average cortical surface.

Quality Control

The reconstruction of the inflated surface should be smooth and free from holes, bumps, and other defects. The data for each subject were reviewed for such topological inaccuracies prior to the group analysis, and the surfaces from 4 subjects were found to contain topological errors. A review of the data from these 4 subjects revealed that for 2 of the subjects, the cerebellum had been detached during the skull stripping. This problem was corrected by manually editing the volume in order to reinsert the cerebellum; the reconstruction was then recomputed and resulted in surfaces with the proper topology. Two of the subjects (one normal control and one sickle cell patient) were eliminated from the cohort as their reconstructions had widespread small topological errors caused by errors in the segmentation and/or generation of the surfaces. These were probably a result of either poor signal to noise ratio (SNR) or motion during the volumetric MRI

acquisition. Hence, there were a total of 57 subjects with cortical reconstructions of acceptable quality.

Results

Parametric maps were calculated for each of the 2 groups (younger and older subjects) on the null hypothesis of no significant difference between the thickness intercepts (i.e., age = 0). The parametric maps for the 2 groups shown in Figure 1 *a,b* were generated using a lower threshold of $P < 0.05$ and a saturation point of $P < 0.001$. Inspection of the 2 maps shows a much greater significance and extent of cortical thinning in the older group. Areas that exhibited significant bilateral thinning of the medial cortex included the precuneus, the paracentral, and the superior frontal regions. The temporal and frontal areas were among the regions that showed significant thinning of the lateral surface in the older group.

Consideration of the data from Lenroot et al. (2007) and Shaw et al. (2008) leads us to conclude that there are considerable confounds in interpreting the linear model over the younger age cohort but, conversely, leads us to have confidence in the results of the linear model on the older age group. In the younger cohort, the cited data indicate that the cortical volume over the younger age range is not a monotonic function but instead has more of a quadratic form with an increase in cortical volume leading to a peak and a subsequent decline in cortical volume. Furthermore, there are region-, disease-, and gender-specific shifts in the age at which the maximum volume is attained (Lenroot et al. 2007; Shaw et al. 2007, 2008). In view of these confounds, the validity of the linear model used in the generation of the statistical parametric maps of mean cortical thickness in the younger group is questionable. For the older cohort, the cited data indicate that the expected pattern for the healthy controls in this age range over most of the brain is a monotonic decline; hence, it is

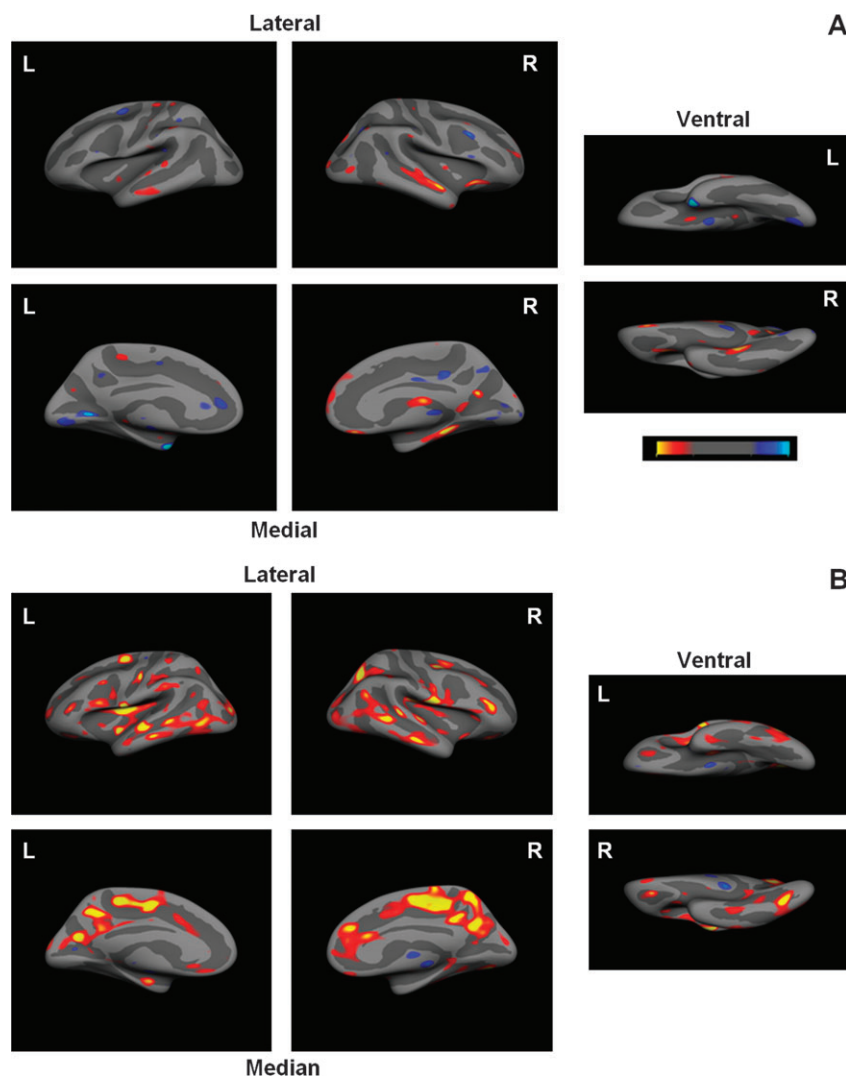


Figure 1. In all the figures, the regions in the parametric maps corresponding to areas of statistical significance ($P < 0.05$) are shown as a color overlay on the average surface derived from the relevant group. The light blue (when present) and yellow colors denote regions where $P < 0.01$, that is, significance greater than 99% confidence interval. (A) Shows maps of statistically significant cortical thinning for the younger group (see Table 1 for details). A blue overlay denotes areas where the cortex of the SCD group is thicker than that in the normal controls; a red/yellow overlay denotes the inverse, that is, SCD group thinner than controls. (B) Shows maps of statistically significant cortical thinning for the older group (see Table 2 for details). A blue overlay denotes areas where the cortex of the SCD group is thicker than that in normal controls; a red/yellow overlay denotes the inverse, that is, SCD group thinner than controls.

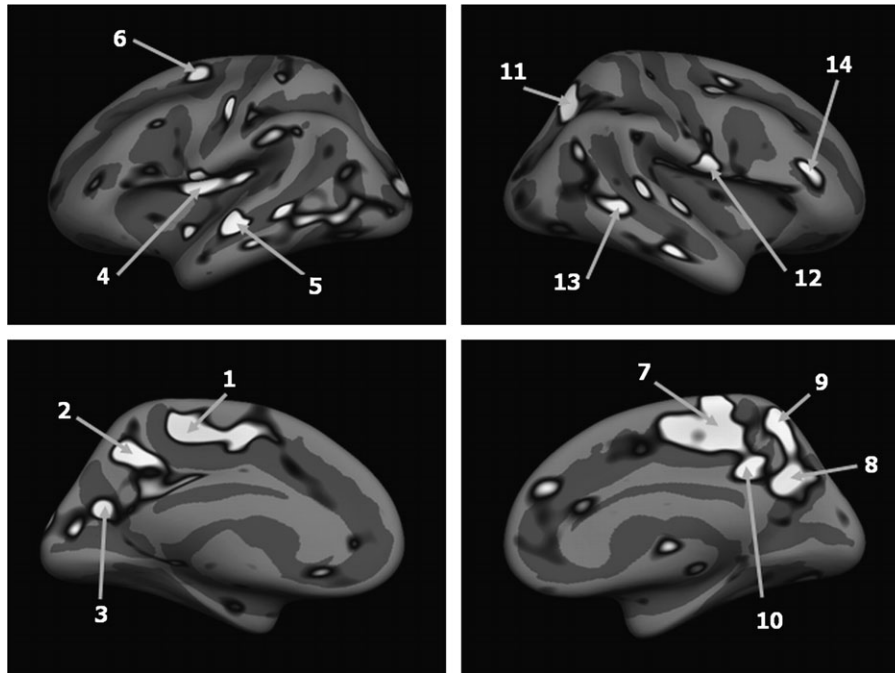


Figure 2. The location of the ROIs.

reasonable that the linear model may be valid for this group. In order to more carefully examine the linear model in the 2 age groups, we choose 14 regions of interest (ROIs) including the most significant regions of thinning indicated by the significance map in the older group shown in Figure 2. The average surfaces for the older and younger group were brought into alignment by the same procedure that was used to align the individual subjects. These ROIs defined on the areas of significant thinning in the older group can then be mapped onto the surface of the younger group average using this alignment. The ROIs could then be mapped onto the individual subjects of both the younger and older group using the alignment transformations calculated during the analysis of the individual groups. The data for all subjects from 4 representative ROIs are shown in Figure 3 along with the linear fits for the older subjects. An analysis of covariance was performed using SPSS for all the ROIs and for each of the 2 age groups, and the results of the analysis are summarized in Table 1. The results indicated that there was no significant difference in the slope values (i.e., age \times disease interaction) for the older group, but that there was a significant slope effect for all but one of the ROIs in the right hemisphere of the younger group. There was no significant difference in the regression line estimates due to gender differences in either age group. The data also indicate that there was no significant disease-related difference in cortical thickness in the younger group; conversely, for the older group, a very significant, disease-related difference in cortical thickness was observed for all of the ROIs.

Discussion

Using a direct, validated measurement of cortical thickness, we found statistically significant thinning of the multiple regions of the cerebral cortex in older children with SCD. For the older subjects, there is a clear distinction between the data points

from the SCD patients and those from the controls, but in the younger patients, no clear separation is observed. Given the complex spatiotemporal dynamics of the cortical development in children below the age of 12 years, we were unable to separate the age, gender, and disease interactions with the limited amount of data included in this study. Thus, we were unable to establish the age range over which the abnormal cortical development occurs; however, we can state that there is a difference present in the older group.

Cortical Thinning and Hypoperfusion

Although we know of no explicit relationship between cortical thickness and cerebral perfusion, it seems reasonable that impaired perfusion could affect the development and maintenance of the cerebral cortex. Animal models of intermittent hypoxia show an effect of neurodegeneration and inflammation (Pena and Ramirez 2005). Intermittent hypoxia is also known to diminish the induction of long-term potentiation (Payne et al. 2004) which could play a role in creating weakly connected networks that are prone to large-scale pruning with loss of neuropil. The most significant areas of cortical thinning in our study were located on the posterior medial surfaces of both hemispheres in the older SCD subjects. These regions lie predominantly in the so-called “watershed” areas of the perfusion territories of the anterior cerebral artery (ACA) and the posterior cerebral artery (PCA). The regions of most significant thinning bilaterally, the precuneus and the posterior cingulate, show a selective vulnerability to acute hypoxia (Laureys et al. 1999) and diffuse brain ischemia (DeVolder et al. 1990). These regions constitute part of the posited “default mode” network (Raichle and Snyder 2007) which consists of a distributed network of regions that show deactivation during the rest periods in positron emission tomography (PET) and fMRI studies and which also exhibit an exceptionally high metabolic rate relative to other brain

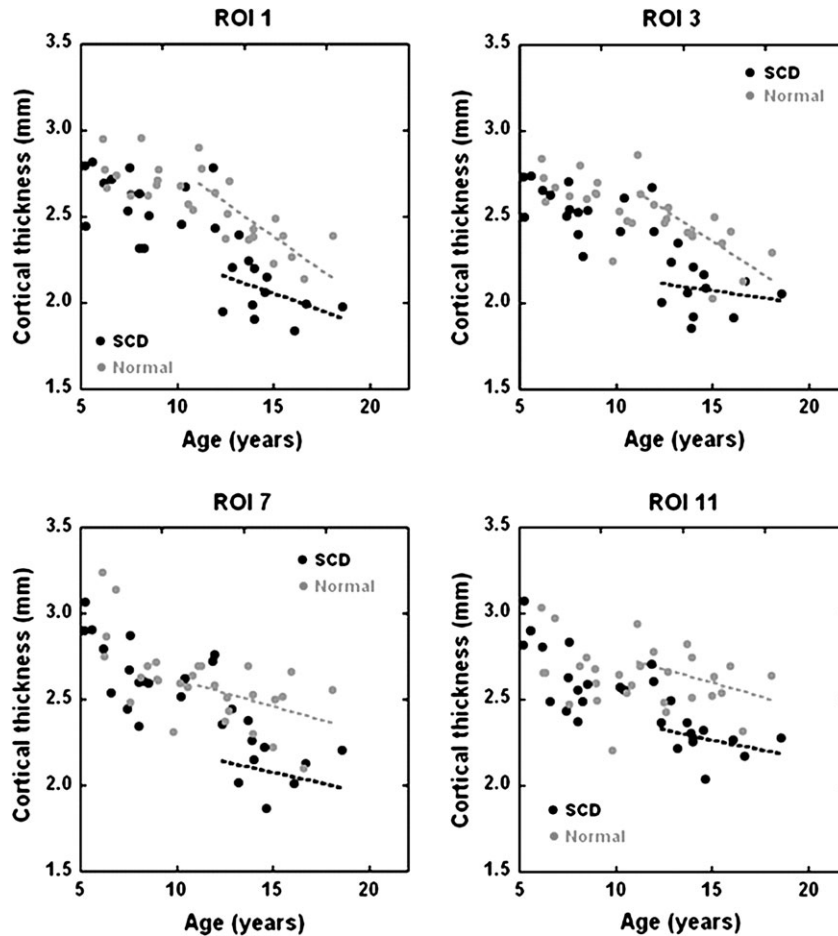


Figure 3. The mean cortical thickness in 4 of the ROIs plotted for all subjects as a function of age. The lines represent the linear fits for the older group.

Table 1

The *P* values from the analysis of covariance for each of the 14 ROIs and for each of the 2 groups (younger and older subjects, respectively)

ROI	Hemisphere	Anatomical location	Younger group			Older group		
			Gender	Disease	Age × disease	Gender	Disease	Age × disease
1	L	Posterior paracentral	0.873	0.402	0.234	0.319	<0.001	0.128
2	L	Superior frontal	0.932	0.908	0.101	0.524	<0.001	0.400
3	L	Precuneus	0.875	0.633	0.770	0.396	<0.001	0.315
4	L	Insula	0.83	0.448	0.170	0.425	<0.001	0.235
5	L	Superior temporal	0.822	0.378	0.398	0.315	<0.001	0.187
6	L	Superior frontal	0.943	0.351	0.359	0.356	<0.001	0.151
7	R	Paracentral	0.491	0.236	0.096	0.363	0.002	0.629
8	R	Precuneus	0.118	0.339	0.014	0.244	<0.001	0.455
9	R	Superior frontal	0.101	0.549	0.025	0.090	<0.001	0.126
10	R	Pre and postcentral	0.129	0.609	0.037	0.069	<0.001	0.109
11	R	Superior parietal	0.227	0.820	0.049	0.222	<0.001	0.444
12	R	Superior frontal	0.123	0.905	0.015	0.211	<0.001	0.442
13	R	Posterior middle temporal	0.108	0.957	0.012	0.154	<0.001	0.647
14	R	Rostral middle frontal	0.114	0.926	0.016	0.161	<0.001	0.662

Note: The ROIs corresponded to areas of significant thinning in the older subjects and hence do not correspond to a particular parcellation. The locations given are the main parcellation present in each ROI. Entries in bold type indicate significant ($p \leq 0.05$) values.

regions in PET studies (Raichle et al. 2001). It would seem logical that the high metabolic requirements of these regions coupled with the high cerebral blood flow (CBF) and the chronic hypoxia associated with SCD would make these regions susceptible to abnormal development. Other recent results indicate that the default mode network matures at approximately 12 years of age (Fair et al. 2008), which may

partially explain the absence of thinning in precuneus and posterior cingulate in the younger group, despite the higher metabolism of young children. It is also noteworthy that in studies of Alzheimer-type cognitive decline, the posterior cingulate and the precuneus show early indications of hypoperfusion (Benson et al. 1983) and are associated with significant cortical thinning (Du et al. 2007).

The medial prefrontal cortex is also associated with the default mode and also has a relatively high metabolic rate at rest; however, no cortical thinning was detected in this region in the older sickle cell group. This may reflect the effect of a better blood supply to this non-watershed region. The regions of significant thinning on the lateral surfaces are more scattered and multifocal, and only in some cases are they associated with the watershed area between the ACA and PCA. Almost all the regions of thinning on the lateral surfaces were located in sulci rather than on the gyri of the cortex. The neuropsychological manifestations of thinning in the “default mode” brain regions is difficult to assess due to the incomplete understanding of the default mode.

Patients with end-stage renal disease undergoing hemodialysis are also known to suffer from cognitive deficits, cerebral atrophy, and high stroke prevalence. A recent study suggested that these patients suffer from low CBF during the interdialytic cycle and that this, coupled with low cerebral oxygenation levels, may contribute to the etiology of these effects (Prohovnik et al. 2007). The similarities between these results and those from our study suggest that intermittent hypoxia may cause similar problems in a range of diseases. The effect of hemodialysis on our study also has to be considered; however, as only 2 of the SCD patients have had regular transfusions, this cannot explain all the differences observed in our study.

Cortical Thinning and Behavioral Effects

Although no neuropsychological data were acquired for this study, it is of interest to try and relate the functional implications of our findings to the cognitive data in the literature. Unfortunately, as detailed in a recent review of neurocognitive studies in SCD (Berkelhammer et al. 2007), there is significant variability in the findings including some contradictory studies, and only a few studies considered age as a mediating factor. Furthermore, we did not address the possibility of white matter lesions in this study which may affect the functioning of distributed processes.

In general, in children with SCD attention and executive functions appear to be particularly vulnerable. The consensus from a number of studies is that the dorsolateral prefrontal cortex has to be critically involved in executive function (D'Esposito et al. 1995; Collette et al. 1999). However, these studies also showed activity in other areas including the parietal cortex. In a more recent study, a distributed network was found with the frontal lobes areas showing the most significant clusters for activation that did not vary as a function of the frequency that the attention was switched between items in working memory (Garavan et al. 2000) However, there were 2 other large clusters located in the parietal cortex (left inferior parietal lobe and left precuneus) which did vary as a function of the switching frequency. Thus, there is a possible connection between the thinning of the left precuneus seen in our study and the reported declines in executive function seen in children with SCD; however, the actual correlation will depend on the details of the tasks used to measure executive function. Bilateral precuneus activation has also been associated with episodic memory retrieval (Krause et al. 1999); however, a correlation with neurocognitive data is difficult because episodic memory retrieval is not tested in a general neurocognitive battery. Most of the remaining areas of thinning are found in the deep infoldings of the temporal lobes, areas

which are associated with verbal and nonverbal IQ and which are known to be affected negatively in SCD, even in the absence of ischemia, silent infarcts, or vascular damage. Future research in this area should pair neuroanatomical findings with neuropsychological testing specific to the ROIs seen in this study and the related literature in order to explore the functional consequences of cortical thinning.

Limitations

One of the limitations of this study is the size of the SCD and control groups. The end point of this study coincided with a significant upgrade of our 1.5-T scanners and the installation of a 3-T scanner. The difficulty in combining data from different field strengths in the group analysis has been previously documented (Han et al. 2006; Jovicich et al. 2006). Thus, any additional cases scanned using the 3-T scanner could not be combined with the results from the current 1.5-T study. There has been recently a reported release of the data from the National Institutes of Health MRI study of normal brain development (Evans 2006). The data released include first-year volumetric MRI acquisitions for several hundred children over the pediatric age range. The data could potentially be used to increase the number of normal subjects, but this would be subject to the same problems of differences between scanners from different vendors, interscanner variability among scanners from the same vendor, and potential differences in the imaging hardware and acquisition protocols (Han et al. 2006). Because of the retrospective nature of the recruitment of the patients with SCD, we were unable to perform neuropsychological testing on this population and hence were unable to document if they had any cognitive defects compared with the control population.

As a result of the small sample size, the effects of gender and age on cortical thickness could not be conclusively determined. To our knowledge, the largest cohort for which cortical thickness analysis has been performed to examine gender differences consisted of 176 healthy individuals aged between 7 and 87 years (Sowell et al. 2007). They found that the most significant gender-related differences were in the right association area, that is, posterior temporal and parietal regions when the results were not normalized for height and body size (which is also the case for our data). Because the most significant areas of thinning in our study did not coincide with these areas, it is unlikely that the statistical power of our results on the medial surfaces could be explained by gender-related differences. However, the lack of any gender effects may be the result of the small sample size used in this study. Similarly, the hemispheric differences in the significance of the slope effect for the younger group and the absence of a disease effect in the younger group may simply reflect the fact that the cohort was not large enough to determine accurately the spatiotemporal dynamics of the thinning process in the younger subjects. Other than recruiting a very large number of subjects, the best method of addressing this problem may be to recruit subjects within a rather narrow age range because the temporal development of the cortex can be approximated to a linear function over a short enough time period.

Conclusion

Given the sample size, we cannot be certain that our sampling indicates all regions that are likely to be affected by thinning of

the cortex or that our sampling indicates the areas most at risk. Additionally, without the benefit of postmortem histological studies, it is impossible to know the exact effect of the hypoxia on the cytoarchitecture. However, our results indicate significant selective thinning of several cortical regions in older patients with SCD. Thus, prophylactic treatments to mitigate the neurological deficits encountered in SCD populations would have to begin at an early age if they are to be effective. Further work is needed to better understand the etiology of this thinning and its effects on cognitive performance.

Supplementary Material

Supplementary material can be found at: <http://www.cercor.oxfordjournals.org/>.

Funding

The acquisition of the control data used in this study was funded by a grant from the "Friends research fund", activity number 06694.

Notes

Conflict of Interest: None declared.

Notes

Address correspondence to Richard A. Jones, Department of Radiology, Children's Healthcare of Atlanta, 1001 Johnson Ferry Road, Atlanta, GA 30342, USA. Email: Richard.Jones@choa.org.

References

- Baldeweg T, Hogan AM, Saunders DE, Telfer P, Gadian DG, Khadem-Vargha F, Kirkham F. 2006. Detecting white matter injury in sickle cell disease using voxel-based morphometry. *Ann Neurol*. 59(4):662-672.
- Benson DF, Kuhl DE, Hawkins RA, Phelps ME, Cummings JL, Tsai SY. 1983. The fluorodeoxyglucose 18F scan in Alzheimer's disease and multi-infarct dementia. *Arch Neurol*. 40(12):711-714.
- Berkelhammer LD, Williamson AL, Sanford SD, Dirksen CL, Sharp WG, Margulies AS, Prengler RA. 2007. Neurocognitive sequelae of pediatric sickle cell disease: a review of the literature. *Child Neuropsychol*. 13:120-131.
- Collette F, Salmon E, Van der Linden M, Chicherio C, Belleville S, Degueldre C, Delfiore G, Franck G. 1999. Regional brain activity during tasks devoted to the central executive of working memory. *Cogn Brain Res*. 7:411-417.
- Dale AM, Fischl B, Sereno MI. 1999. Cortical surface-based analysis I. Segmentation and surface reconstruction. *Neuroimage*. 9(2):179-194.
- D'Esposito M, Detre JA, Alsop DC, Shin RK, Atlas S, Grossman M. 1995. The neural basis of the central executive system of working memory. *Nature*. 378:279-281.
- DeVolder AG, Goffinet AM, Bol A, Michel C, de Barsey T, Laterre C. 1990. Brain glucose metabolism in postanoxic syndrome. Positron emission tomographic study. *Arch Neurol*. 47(2):197-204.
- Du A-T, Schuff N, Kramer JH, Rosen HJ, Gorno-Tempini ML, Rankin K, Miller BL, Weiner MW. 2007. Different regional patterns of cortical thinning in Alzheimer's disease and frontotemporal dementia. *Brain*. 130:1159-1166.
- Evans AC. 2006. The NIH MRI study of normal brain development. *Neuroimage*. 30:184-202.
- Fair DA, Cohen AL, Dosenbach NUF, Church JA, Miezin FM, Barch DM, Raichle MA, Petersen SE, Schlaggar BL. 2008. The maturing architecture of the brain's default network. *Proc Natl Acad Sci USA*. 105(10):4028-4032.
- Fischl B, Dale AM. 2000. Measuring the thickness of the human cerebral cortex from magnetic resonance images. *Proc Natl Acad Sci USA*. 97:11044-11049.
- Fischl B, Dale AM, Sereno MI, Tootell RBH, Rosen BR. 1998. A coordinate system for the cortical surface. *Neuroimage*. 7:S740.
- Fischl B, Salat DH, Busa E, Albert M, Dieterich M, Haselgrove C, van der Kouwe A, Killiany R, Kennedy D, Klavness S, et al. 2002. Whole brain segmentation: automatic labeling of neuroanatomical structures in the human brain. *Neuron*. 33:341-355.
- Fischl B, Sereno MI, Dale AM. 1999. Cortical surface-based analysis II: inflation, flattening, and a surface-based coordinate system. *Neuroimage*. 9(2):195-207.
- Fischl B, Sereno MI, Tootell RBH, Dale AM. 1999. High-resolution intersubject averaging and a coordinate system for the cortical surface. *Hum Brain Mapp*. 8:272-284.
- Garavan H, Ross TJ, Li S-J, Stein EA. 2000. A parametric manipulation of central executive functioning. *Cereb Cortex*. 10:585-592.
- Goghari VM, Rehm K, Carter CS, MacDonald AW. 2007. Regionally specific cortical thinning and gray matter abnormalities in the healthy relatives of schizophrenia patients. *Cereb Cortex*. 17:415-424.
- Grueneich R, Douglas RM, Ball W, Kalinyak KA, Noll R, Vannatta K, Wells R. 2004. Relationship of structural magnetic resonance imaging, magnetic resonance perfusion, and other disease factors to neuro-psychological outcome in sickle cell disease. *J Pediatr Psychol*. 29(2):83-92.
- Hadjikhani N, Joseph RM, Snyder J, Tager-Flusberg H. 2006. Anatomical differences in the mirror neuron system and social cognition network in autism. *Cerebral Cortex*. 16:1276-1282.
- Han X, Jovicich J, Salat D, van DKA, Quinn B, Czanner S, Busa E, Pacheco J, Albert M, Killiany R, et al. 2006. Reliability of MRI-derived measurements of human cerebral cortical thickness: the effects of field strength, scanner upgrade and manufacturer. *Neuroimage*. 32:180-194.
- Hillery CA, Panepinto JA. 2004. Pathophysiology of stroke in sickle cell disease. *Microcirculation*. 11:195-208.
- Jovicich J, Czanner S, Greve D, Haley E, Van Der Kouwe A, Gollub R, Kennedy D, Schmitt F, Brown G, MacFall J, et al. 2006. Reliability in multi-site structural MRI studies: effects of gradient non-linearity correction on phantom and human data. *Neuroimage*. 30:436-443.
- Kral MC, Brown RT, Connelly M, Cur'e JK, Besenski N, Jackson SM, Abboud MR. 2006. Radiographic predictors of neurocognitive functioning in pediatric sickle cell disease. *J Child Neurol*. 21:37-44.
- Krause BJ, Schmidt D, Mottaghy FM, et al. 1999. Episodic retrieval activates the precuneus irrespective of the imagery content of word pair associates: a PET study. *Brain*. 122:255-263.
- Kuperberg GR, Broome MR, McGuire PK, David AS, Eddy M, Ozawa F, Goff D, West WC, Williams SC, van der Kouwe A, et al. 2003. Regionally localized thinning of the cerebral cortex in schizophrenia. *Arch Gen Psychiatry*. 60(9):878-888.
- Laureys S, Lemaire C, Maquet P, Phillips C, Franck G. 1999. Cerebral metabolism during vegetative state and recovery to consciousness. *J Neurol Neurosurg Psychiatry*. 67(1):121.
- Lenroot RK, Gogtay N, Greenstein DK, Wells EM, Wallace GL, Clasen LS, Blumenthal JD, Lerch J, Zijdenbos AP, Evans AC, et al. 2007. Sexual dimorphism of brain development trajectories during childhood and adolescence. *Neuroimage*. 36:1065-1073.
- Ohene-Frempong K, Weiner SJ, Sleeper LA. 1998. Cerebrovascular accidents in sickle cell disease: rates and risk factors. *Blood*. 91:288-294.
- Payne RS, Goldbart A, Gozal D, Schurr A. 2004. Effect of intermittent hypoxia on long term potentiation in rat hippocampal slices. *Brain Res*. 1029(2):195-199.
- Pegelow CH, Macklin EA, Moser FG, et al. 2002. Longitudinal changes in brain magnetic resonance imaging findings in children with sickle cell disease. *Blood*. 99:3014-3018.
- Pena F, Ramirez JM. 2005. Hypoxia-induced changes in neuronal network properties. *Mol Neurobiol*. 32:251.
- Platt OS, Brambilla DJ, Rosse WF, et al. 1994. Mortality in sickle cell disease. Life expectancy and risk factors for early death. *N Engl J Med*. 330:1639-1644.

- Prohovnik I, Post J, Uribarri J, Lee H, Sandu O, Langhoff E. 2007. Cerebrovascular effects of hemodialysis in chronic kidney disease. *J Cereb Blood Flow Metab.* 27:1861-1869.
- Raichle ME, MacLeod AM, Snyder AZ, Powers WJ, Gusnard DA, Shulman GL. 2001. A default mode of brain function. *Proc Natl Acad Sci USA.* 98:676-682.
- Raichle ME, Snyder AZ. 2007. A default mode of brain function: a brief history of an evolving idea. *Neuroimage.* 37(4):1083-1090.
- Rosas HD, Liu AK, Hersch S, Glessner M, Ferrante RJ, Salat DH, van der Kouwe A, Jenkins BG, Dale AM, Fischl B. 2002. Regional and progressive thinning of the cortical ribbon in Huntington's disease. *Neurology.* 58:695-701.
- Shaw P, Eckstrand K, Sharp W. 2007. Attention-deficit/hyperactivity disorder is characterized by a delay in cortical maturation. *Proc Natl Acad Sci USA.* 104(49):19649-19654.
- Shaw P, Kabani NJ, Lerch JP, et al. 2008. Neurodevelopmental trajectories of the human cerebral cortex. *J Neurosci.* 28(14):3586-3594.
- Sowell ER, Peterson BS, Kan E, Woods RP, Yoshii J, Bansal R, Xu D, Zhu H, Thompson PM, Toga AW. 2007. Sex differences in cortical thickness mapped in 176 healthy individuals between 7 and 87 years of age. *Cereb Cortex.* 17:1550-1560.
- Steen RG, Emudianughe T, Hunte M, Glass J, Wu S, Xiong X, Reddick WE. 2006. Brain volume in pediatric patients with sickle cell disease: evidence of volumetric growth delay? *AJNR Am J Neuroradiol.* 26:455.
- Steen RG, Fineberg-Buchner C, Hankins G, Weiss L, Prifitera A, Mulhern RK. 2005. Cognitive deficits in children with sickle cell disease. *J Child Neurol.* 20:102-107.
- Steen RG, Langston JW, Ogg RJ, Xiong X, Ye Z, Wang WC. 1999. Diffuse T1 reduction in gray matter of sickle cell disease patients: evidence of selective vulnerability to damage? *Magn Reson Imaging.* 17(4):503-515.
- Watkins KE, Hewes DK, Connelly A, et al. 1998. Cognitive deficits associated with frontal-lobe infarction in children with sickle cell disease. *Dev Med Child Neurol.* 40:536-543.